


Current role of ultrasound in hemodialysis access evaluation

Meola Mario¹ , Jose Ibeas²  and Jan Malik³ 

The Journal of Vascular Access
1–7
© The Author(s) 2021
Article reuse guidelines:
sagepub.com/journals-permissions
DOI: 10.1177/11297298211034638
journals.sagepub.com/home/jva


Abstract

Physical examination (PE) is considered the backbone before vascular access (VA) placement, during maturation period and for follow-up. However, it may be inadequate in identifying suitable vasculature, mainly in comorbid patients, or in detecting complications. This review highlights the advantages of ultrasound imaging to manage VA before placement, during maturation and follow-up. Furthermore, it analyses the future perspectives in evaluating early and late VA complications thank to the availability of multiparametric platforms, point of care of ultrasound, and portable/wireless systems. Technical improvements and low-cost systems should favor the widespread ultrasound-based VA surveillance programs. This significant turning point needs an adequate training of nephrologists and dialysis nurses and the standardization of exams, parameters, and procedures.

Keywords

Vascular access, B-Mode and pulsed wave Doppler, vascular access surveillance, ultrasound instrumentation, point of care of ultrasound

Date received: 7 January 2020; accepted: 5 July 2021

Introduction

Correct management of native arteriovenous fistula (AVF) or arteriovenous grafts requires specific knowledge and expertise and a multidisciplinary team approach. Early referral of uremic patients to a nephrologist—usually considered the vascular access (VA) coordinator—is the mainstay to increase fistula placement, to ensure a correct and multidisciplinary approach, reduce the primary failure rate, and improve the cumulative VA patency.¹

Before VA creation, patients' presurgical assessment has been based on physical examination (PE) for a long time, and phlebography was the gold-standard imaging.^{2,3} Currently, ultrasound (US) and pulsed wave Doppler (PWD) are the first-line imaging for VA management.^{4–6} Safety, availability, and reliability are the main advantages of ultrasound modalities.

Therefore, non-invasive imaging impact has remarkably increased in the last years because most AVF with an inflow or outflow stenosis can be treated with percutaneous transluminal angioplasty (PTA) to increase long-term survival.^{2,7} Meanwhile, US platforms have dramatically improved since the 1990s, when the first reports in VA imaging were published. Both multiparametric top-line systems and portable or pocket-sized systems can be used

at bedside, operating, and hemodialysis rooms. Thus, the question is why US, now considered as the fifth pillar of physical semiotics, should not be systematically used in VA management.

This monothematic issue aims to update the role of the US in VA. It suggests the widespread use of Point-Of-Care Ultrasound (POCUS) with miniaturized, portable handheld devices using an imaging program in preoperative mapping, maturation period, and VA surveillance to avoid the major complications. In other words, it is time to add the *insonation* as the fifth pillar of the VA examination.

¹Institute of Life sciences, Department of Internal Medicine, Sant'Anna School of Advanced Studies, University of Pisa, Pisa, Italy

²Nephrology Department, Parc Taulí University Hospital, Parc Taulí Research and Innovation Institute (I3PT), Autonomous University of Barcelona, Barcelona, Spain

³Center for Vascular Access, General University Hospital, First Faculty of Medicine, Charles University, Prague, Czech Republic

Corresponding author:

Meola Mario, Institute of Life sciences, Department of Internal Medicine, Sant'Anna School of Advanced Studies, University of Pisa, Via Roma 45, Pisa 56100, Italy.
Email: mario.meola@unipi.it

Table 1. Physical and B-Mode/PWD findings of arteries related to arteriovenous fistula prior to access placement.

Diagnosis/test	Physical examination	B-Mode and PWD
Normal	No information	IMT, PWV, PSV >25–30 cm/s in radial artery, >40–50 cm/s in brachial artery Blood flow rate >40–50 ml/min in brachial artery
Atherosclerosis, wall pathologies (age-related, diabetes, CKD, connective tissue disorders)	No information	Number, extension, nature of plaques (lipoid, fibro-sclerotic, calcific), lumen diameter (>2 mm), single or multiple stenosis (PSV, DV, spectral broadening, aliasing)
Pulse examination	Quality score (normal, diminished, Corrigan pulse, absent)	Spectral curve morphology (high resistance flow), systolic/diastolic ratio, RI, PWV
Segmental blood pressure measurement	Differential pressure between arms >20 mmHg (subclavian stenosis)	Stenosis of right subclavian artery at the origin (PSV, DV, spectral broadening, aliasing) Indirect signs of stenosis on the left side
Patency of palmar arch	Allen test	Allen test modified with PWD Reactive hyperaemia test (RI <0.70)
Congenital anomalies	No information	Bifurcation's anomalies of brachial artery course anomalies of radial and ulnar artery

PWD: pulsed wave Doppler; CKD: chronic kidney disease; IMT: intimal medial thickness; PSV: peak systolic velocity; DV: diastolic velocity; RI: resistive index; PWV: pulse wave velocity.

Table 2. Physical and B-mode/PWD examination of vein related to arteriovenous fistula prior to access placement.

Diagnosis/test	Physical examination	B-Mode and PWD
Cephalic, basilic, and median antecubital veins anatomy	Vein course on the forearm and arm surface is not always evident also using a blood pressure cuff inflated at 40–50 mmHg	Anomalies, course, luminal diameter (>2.5 mm), deep and distance from the artery, length of straight segment for cannulation, continuity with arm, and central veins Anatomy of median antecubital and perforating vein Collaterals and valve apparatus
Wall quality	Distensibility (venous filling time test; dilation after placing tourniquet or blood pressure cuff inflated at 40–50 mmHg) Stenosis and fibrosis	Variation of luminal diameter (25%–50%) after placing tourniquet or blood pressure cuff inflated at 40–50 mmHg Centripetal, continuous low-resistance flow Absence of obstruction and fibrosis
Central vein patency	No information	Absence of arterial-like accelerations in the sampled trait “W” spectral modulation in the subclavian and jugular vein
Congenital anomalies	No information	Variations of anatomy Presence of cephalic vein side branches referred to as accessory veins

Objectives and accuracy of physical examination

The National Kidney Foundation—Kidney Disease Outcomes Quality Initiative (NKF-K/DOQI) guidelines 2006 have already pointed out the pivotal role of clinical history and PE before VA creation.⁴ Physical examination should evaluate both arterial and venous patency (Tables 1 and 2).⁸

Physical findings of a mature AVF are related to hemodynamic changes due to by-pass implantation, fall of peripheral resistance, and evidence of turbulent flow in the anastomotic site. Blood by-pass causes a palpable thrill on AVF and a bruit or “swishing” sound at auscultation. Both these signs indicate arterial and venous blood

flow and fistula patency.⁹ A systolic rough, discontinuous, gunshot-like bruit or the onset of a discontinuous, pneumatic drill-like pulsatility or the disappearance of the thrill along the draining vein are all direct signs of stenosis. Collateral veins or aneurysms reinforce the suspicion of stenosis.¹⁰

Palpatory findings associated with juxta-anastomotic venous stenosis include hyper-pulsatility at the anastomosis site, systolic-only thrill perception, and abrupt pulse disappearance across the stenosis site. In addition, flow diversion in collateral veins is often visible and palpable.

Complications of mature AVF can be detected with PE.¹⁰ Two well-known tests, the arm elevation and pulse augmentation test, may easily detect outflow and inflow complications, but they are poorly applicable in AVG. Palpatory

Table 3. Physical and B-Mode/CD/PWD findings of early and late AVF stenosis.

Features	Physical examination	B-Mode and PWD
Normal	Thrill. Very prominent, continuous only at the anastomosis Pulse. Soft and easily compressible Bruit. Low pitch, continuous, systo-diastolic	Artery diameter >4 mm and vein diameter >6 mm Flow rate of brachial artery >600–800 ml/min. Absence of arterial-like acceleration-point in draining vein and tributary artery No thrombosis or myxoid valve
Juxta-anastomotic venous stenosis	Strong pulse and systolic thrill at the anastomosis Thrill disappearance downstream the point of stenosis Development of accessory branches	Vein lumen diameter <2–3 mm Arterial-like accelerations (PSV >250–300 cm/s), spectral broadening, aliasing, and color bruit RI and S/D ratio Increase in tributary artery Blood flow-rate fall in tributary artery
Strength of arterial inflow	Pulse strength. Very strong = good inflow; weak = poor inflow AVF pulsatility = vein stenosis	Arterial calibre (>4–4.5 mm) Low-resistive flow pattern (IR <0.50; S/D ratio <1.5–2) Brachial artery flow-rate >600–800 ml/min
Inflow stenosis	Q_p stress test positive	Arterial-like accelerations (PSV >250–300 cm/s), spectral broadening, aliasing, and color bruit (tributary artery or juxta-anastomotic tract) Slow of venous flow without systolic reinforcement Collateral vein
Outflow stenosis	Thrill very prominent at site of stenosis Pulse systolic knock High pitched, discontinuous, only systolic bruit When arm is elevated, distally to point of stenosis the vein distended, while proximal portion remain collapsed Aneurysm development upstream from venous stenosis (insertion needle)	Arterial-like accelerations (PSV >250–300 cm/s), spectral broadening, aliasing, and color bruit). Fall of brachial flow-rate

findings associated with juxta-anastomotic venous stenosis include hyper-pulsatility at the anastomosis site, systolic-only thrill perception, and abrupt pulse disappearance across the stenosis site. Flow diversion in collateral veins is often visible and palpable. The persistence of a palpable thrill in the anastomosis site after occlusion of the outflow vein is an indirect sign of collateral circles patency. The physical examination can also detect complications of mature VA. Once again, the presence of a swollen arm with subcutaneous venous collaterals and draining vein aneurysms may suggest central vein stenosis.

Nevertheless, B-Mode and PWD provide more details to understand VA morphological and functional changes (Table 3).

Advantages of integrating PE with US-based techniques

Physical examination may be incomplete for both VA planning and management. B-Mode and PWD help choose the anastomotic site, improve pre- and postoperative surveillance, and indicate cannulation time, especially when PE is inconclusive (Tables 1 and 2).¹¹ Some guidelines support the PWD usefulness in preoperative mapping and suggest this imaging modality as a screening test to detect stenosis and perform pre-emptive interventions to avoid VA loss.^{12,13} However, the new European Renal Best

Practice (ERBP) guidelines on VA and KDOQI-2019 clinical practice guideline revision for VA recommend a different approach.^{14,15}

In our opinion, PWD may play a pivotal role in every aspect of VA care and might be considered the first-line imaging modality in patients needing a VA. PWD gives both morphologic and functional data about upper limb arterial and venous vessels. This information is particularly useful in obese patients with diabetes mellitus and arteriosclerosis or in the elderly and pediatric population. In these cases, calcified and noncompliant arteries and small sclerotic veins that negatively affect the remodeling and maturation rates can be easily detected using US modalities.¹⁶

Preoperative mapping

At US, the upper limb veins show a thin wall that completely collapse with transducer compression, while their diameter increases when a tourniquet is placed at the proximal segment. Data that have to be evaluated before AVF creation are veins depth, diameter, course and length, congenital anomalies, and fibrotic segments. Perforating vein morphology and patency at the elbow should always be assessed. An increase >25% (or >50% in the most favorable cases) in the vein diameter after application of a tourniquet is a sign of normal vein wall elasticity (Table 2). In upper limb veins, the spectral curve is continuous,

centripetal, and generates a blowing wind-like sound. However, there is considerable variability in the normal venous waveforms due to breathing, right heart function, and blood volume.¹⁷

Central vein waveform is multiphasic due to the modulations induced by breathing, central venous pressure variations during systole and diastole. This pattern provides an indirect sign of venous patency of proximal vessels with respect to the sampling point. For example, a phased waveform through the subclavian or jugular vein sampling means that the proximal brachiocephalic trunk and superior vena cava are not stenotic. In the preoperative setting, if the waveform pattern is flat and weak without any phasic modulations, phlebography, or second level imaging should investigate a central venous occlusion of the brachiocephalic vein or superior vena cava.

Sonographic evaluation of venous anatomy is pivotal in the choice of the anastomosis site. In adulthood, the efferent vein chosen for the anastomosis should have a diameter >2.0–2.5 mm, especially in patients with arterial wall damage and flow impairment due to age, atherosclerosis, and diabetes, because this condition is favorable both for primary survival and success in the revision of malfunctioning AVF.^{18,19}

On the arterial side, the main checkpoints are the brachial artery, brachial bifurcation, ulnar and radial arteries. The radial artery course should be carefully sampled to find the artery sites closest to the cephalic vein to create an anastomosis with a correct angle. This procedure reduces the risk of reactive neointimal hyperplasia.

The arterial parameters to be assessed are the diameter, the extension of atheromatous plaques, the intimal-medial thickness, the spectral curve in rest conditions (peak systolic velocity, mean or peak average velocity), and the blood flow rate (Table 1). The optimal arterial diameter for creating an AVF is 2 mm, and the minimal blood flow volume in the brachial artery is >50 ml/min, as it has been proved that a diameter <1.5 mm is associated with a higher risk of access dysfunction and lack of arterial dilation.^{20,21}

The superficial and deep palmar arches' patency and perfusion of the distal circulation should be evaluated by using the reactive hyperaemia test. The test is based on the spectral curve recorded in the radial artery in basal conditions, after fist closing for 2 min and immediately after fist opening. If significant vasodilation appears in this last phase of the test and the spectral curve shows a low-resistance pattern (Resistive Index <0.70), the test indicates patency of the palmar arches and hand vessels. Consequently, the creation of an AVF is at low risk of steal syndrome. The color sampling of arteries and veins should be obtained using a 10°–20° steering, while spectral analysis can be obtained using a 60° angle to standardize the results.

After AVF implantation, the most accurate predictors of adequate access maturation are the blood flow volume,

remodeling, and dilation of the feeding artery and draining vein. These parameters can be reliably calculated through a US examination. A recent study suggests that fistula blood flow rates measured at the proximal artery and in the draining vein are comparable one to each other and with the values obtained by phase-contrast magnetic resonance imaging if the measurements of vessels lumen diameter are accurate.²² However, a draining vein diameter <4 mm and a flow rate <500 ml/min are associated with a low probability of adequate maturation.²³ After AVF creation, PWD measurements of blood flow rates at 2 weeks may be useful in the early identification of fistulas that are unlikely to mature correctly.²⁴ Flow rates calculated by PWD correlate with the values measured with the US dilution method ($R^2=0.83$).²⁵

Evaluation of early and late complications: B-mode and Doppler criteria of stenosis

Venous stenosis may be either an early or a late complication of fistula, and it is the most common cause of access failure and dialysis inadequacy. The VA stenosis alters regional hemodynamic and may cause access flow volume decline, followed by recirculation $\geq 12\%$, reduction of Kt/V ratio, high venous pressure (>200 mmHg), thrill reduction, and post-dialytic bleeding.^{26,27} More proximal outflow vein stenosis increases the venous pressure and could lead to hand edema. In newly fistulas, the juxta-anastomotic stenosis in inflow or outflow is primarily caused by venous neointimal hyperplasia and inward vascular remodeling (venous constriction) stimulated by endothelial inflammatory-like pathways due to shear stress variations.

PTA has become the current standard treatment of this complication despite the stenosis relapses.²⁸ Adequate surveillance with PWD imaging allows early diagnosis of the venous stenosis and proper selection of the cases referred to procedure. Defining morphological and hemodynamic criteria of stenosis at ultrasound is currently challenging because of the lack of standardized values and procedures. The increase of the peak systolic velocity (PSV) and diastolic velocity in stenotic segments (juxta-anastomotic and distal segment of the outflow vein in the native fistula, venous anastomosis of prosthetic graft), spectral broadening, and artifacts such as aliasing and perivascular color bruit are the typical signs of stenosis.

Arterial stenosis represents only 8% of all vascular access stenosis. It is associated with age-related diseases and may be suspected when PSV values in the radial artery are greater than 200 cm/s (compared with the upstream segment of the vessel—PSV ratio >2–2.5).^{4,6} Conversely, the diagnosis of draining vein stenosis is more difficult. In this case, a segmental increase in the PSV (>300 cm/s) in the vein is to be considered critical if the increase of PSV

is associated with a reduction of blood flow rate in the brachial artery (<500 ml/m or fall of 25% in the last month when the blood flow rate is <1000 ml/min).^{5,6} PWD measurements compared to venography have shown an overall sensitivity ranging from 87% and 100% and specificity between 85% and 97%.^{28,29} Considering that PTA is the choice treatment for stenosis and obstruction of VA and that the costs related to the administration of repeated PTA and drug-eluting/coated balloon are elevated, more trials are needed to define parameters and indications of the therapeutic procedures.

Point-of-care ultrasound revolution

The concept of focused imaging increasingly influences current clinical practice. The physician has to focus only to few US key points instead of performing an extensive PWD examination. Point-Of-Care Ultrasound (POCUS) is the most known and promising application of focused imaging. It refers to the practice of trained medical professionals using US to diagnose problems wherever a patient is treated, either in a modern hospital, an ambulance, or a remote place. Its benefits include the availability of a wider range of medical personnel than the one needed for a specialized and extensive US examination. Therefore, this procedure is very helpful in emergency settings where prompt referral to a specialist is not always possible. The common belief that POCUS cannot replace extensive US examination is based on the bedside context, the lower required level of examiner's US proficiency, and the goal-directed nature of the POCUS examination.

Consequently, specific measures are required to distinguish the clinical context in which each kind of examination should be performed (Figure 1).³⁰ Focused imaging has found its utility in clinical practice by considering "insonation" as the fifth pillar of physical examination.³¹ POCUS has properly and cost-effectively modified the workup of common clinical presentations.³² The improved clinical outcomes using POCUS already justify the widespread of US practice among nurses and non-specialists of ultrasound imaging. The lack of specific training requirements further stimulates the use of POCUS since no standardized teaching and assessment criteria are available to date.

Given the progressive diffusion of focused imaging, it is appropriate to evaluate whether and how its use in clinical practice will affect VA planning and/or follow-up. Evidence about POCUS use in VA management is still very poor; a recent study has shown a decreased primary and secondary failure rate of AVF when the preoperative mapping was performed with POCUS versus PE.³³

Investigations are ongoing to assess whether POCUS can improve vessel cannulation compared to "blind" PE-based cannulation. However, to our knowledge, a direct comparison with specialized and extensive US

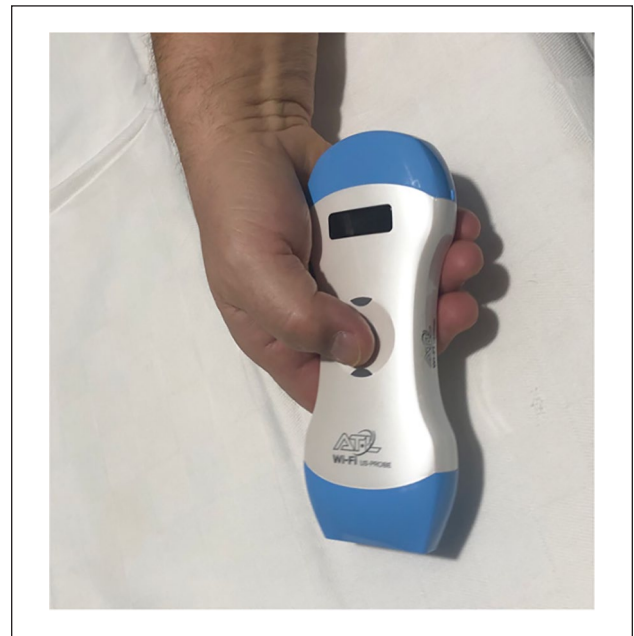

Figure 1. Wireless ultrasound probe.

mapping is still lacking. Moreover, the clinical contexts of comparison between PE, comprehensive ultrasound, and POCUS are multiple. They include preoperative mapping, maturation period, VA surveillance, and follow-up to detect early and late complications. POCUS could be implemented to detect early and late VA complications, but it needs to be assessed through feasibility studies that are still lacking to date.

Standardization of examination, parameters, and procedures

In routine US management of VA, there are the same issues present in all the subspecialties of sonography, especially regarding the lack of a standardized and shared protocol for PWD examination and interpretation. However, a nephrologist should always manage VA clinical process using PWD, from planning to follow-up, even if the skills required to obtain the best results are not limited to normal specialist knowledge. A PWD operative protocol for VA management is mandatory, however to date, it is still lacking. The European Federation of Societies for Ultrasound in Medicine and Biology (EFSUMB) has published the minimum training recommendations for medical ultrasound practice. However, there is no specific section on VA management in the vascular appendix³⁴ because data about VA ultrasound are recent and not always conclusive. Therefore, ultrasound societies' standardization of US exams and procedures should be performed together with multidisciplinary teams skilled in VA US management. Examples of parameters requiring urgent standardization among practitioners include preoperative criteria for

assessing outflow vein stenosis, and algorithms for the postoperative evaluation of the access flow rate.

Conclusion

An accurate PE in preoperative period and a continuous VA follow-up during and after the maturation period should be coupled with PWD examination. In this monothematic supplement, the role of ultrasound in the evaluation of early and late complications of VA is extensively considered. The prospective and future of US surveillance are also analyzed, considering the technological advances and the widespread use of US-based techniques. In the next future, US-based surveillance will probably be the routine procedure. The real challenge will be adequate training for nephrologists and dialysis nurses and the standardization of exams, parameters, and procedures.

Declaration of conflicting interests

The author(s) declared no potential conflicts of interest with respect to the research, authorship, and/or publication of this article.

Funding

The author(s) disclosed receipt of the following financial support for the research, authorship, and/or publication of this article: JM is supported by the grant of the Agency of Health Research of the Czech Republic 17-31796A.

ORCID iDs

Meola Mario  <https://orcid.org/0000-0002-1330-2820>

Jose Ibeas  <https://orcid.org/0000-0002-1292-7271>

Jan Malik  <https://orcid.org/0000-0002-2386-3293>

References

1. Rayner HC, Pisoni RL, Gillespie BW, et al. Creation, cannulation and survival of arteriovenous fistulae: data from the Dialysis Outcomes and Practice Patterns Study. *Kidney Int* 2013; 63: 323–330.
2. Asif A, Leon C, Orozco-Vargas LC, et al. Accuracy of physical examination in the detection of arteriovenous fistula stenosis. *Clin J Am Soc Nephrol* 2007; 2: 1191–1194.
3. Salman L and Beathard G. Interventional nephrology: physical examination as a tool for surveillance for the hemodialysis arteriovenous access. *Clin J Am Soc Nephrol* 2013; 8: 1220–1227.
4. Vascular access 2006 workgroup. Clinical practice guidelines for vascular access. *Am J Kidney Dis* 2006; 48(Suppl. 1): S176–S247.
5. Lomonte C, Meola M, Petrucci I, et al. The key role of color Doppler ultrasound in the work-up of hemodialysis vascular access. *Semin Dial* 2015; 28: 211–215.
6. American College of Radiology (ACR); Society of Radiologists in Ultrasound (SRU); American Institute of Ultrasound in Medicine (AIUM). AIUM practice guideline for the performance of a vascular ultrasound examination for postoperative assessment of dialysis access. *J Ultrasound Med* 2014; 33: 1321–1332.
7. Tordoir JHM, Zonnebeld N, van Loon MM, et al. Surgical and endovascular intervention for dialysis access maturation failure during and after arteriovenous fistula surgery: review of the evidence. *Eur J Vasc Endovasc Surg* 2018; 55: 240–248.
8. Woo K, Ulloa J, Allon M, et al. Establishing patient-specific criteria for selecting the optimal upper extremity vascular access procedure. *J Vasc Surg* 2017; 5: 1089–1103.
9. Windus DW. Evaluation for vascular access dysfunction. In: Nissenson AR and Fine RN (ed.) *Handbook of dialysis therapy*. 4th ed. Philadelphia, PA: Saunders–Elsevier, 2008, pp.37–48.
10. Malovrh M. Postoperative assessment of vascular access. *J Vasc Access* 2014; 15(Suppl. 7): 10–14.
11. Aishwarya KC, Srinath MG, Desai SC, et al. Value of preoperative sonographic vascular evaluation of haemodialysis access in upperlimb. *J Clin Diagn Res* 2014; 8(12): RC06–RC10.
12. Ibeas J, Roca-Tey R, Vallespín J, et al. Spanish clinical guidelines on vascular access for haemodialysis. *Nefrologia* 2017; 37(Suppl. 1):1–191.
13. Schmidli J, Widmer M, Basile C, et al. Editor's choice – vascular access: 2018 clinical practice guidelines of the European society for vascular surgery (ESVS). *Eur J Vasc Endovasc Surg* 2018; 55: 757–818.
14. Gallieni M, Hollenbeck M, Inston N, et al. Clinical practice guideline on peri- and postoperative care of arteriovenous fistulas and grafts for haemodialysis in adults. *Nephrol Dial Transplant* 2019; 34(Suppl. 2): ii1–ii42.
15. Lok EC, Huber TS, Lee T, et al. KDOQI clinical practice guideline for vascular access: 2019 update. *Am J Kidney Dis* 2020; 75: s1–s164.
16. Farrington CA, Robbin ML, Lee T, et al. Postoperative ultrasound, unassisted maturation, and subsequent primary patency of arteriovenous fistulas. *Clin J Am Soc Nephrol* 2018; 13(9): 1364–1372.
17. Selis JE and Kadakia S. Venous doppler sonography of the extremities: a window to pathology of the thorax, abdomen, and pelvis. *AJR Am J Roentgenol* 2009; 193: 1446–1451.
18. Yan Y, Ye D, Yang L, et al. A meta-analysis of the association between diabetic patients and AVF failure in dialysis. *Ren Fail* 2018; 40: 379–383.
19. Lok CE, Allon M, Moist L, et al. Risk equation determining unsuccessful cannulation events and failure to maturation in arteriovenous fistulas (REDUCE FTM I). *J Am Soc Nephrol* 2006; 17: 3204–3212.
20. Malovrh M. Non-invasive evaluation of vessels by duplex sonography prior to construction of arteriovenous fistulas for haemodialysis. *Nephrol Dial Transp* 1998; 13: 125–129.
21. Parmar J, Aslam M and Standfield N. Pre-operative radial arterial diameter predicts early failure of arteriovenous fistula (AVF) for haemodialysis. *Eur J Vasc Endovasc Surg* 2007; 33: 113–115.
22. He Y, Shiu YT, Pike DB, et al. Comparison of hemodialysis arteriovenous fistula blood flow rates measured by Doppler ultrasound and phase-contrast magnetic resonance imaging. *J Vasc Surg* 2018; 68: 1848–1857.

23. Jemcov TK. Morphologic and functional vessels characteristics assessed by ultrasonography for prediction of radiocephalic fistula maturation. *J Vasc Access* 2013; 14: 356–363.
24. Robbin ML, Greene T, Cheung AK, et al.; Hemodialysis Fistula Maturation Study Group. Arteriovenous fistula development in the first 6 weeks after creation. *Radiology* 2016; 279: 620–629.
25. Kairaitis LK, Collett JP and Swinnen J. Diameter of inflow as a predictor of radiocephalic fistula flow. *J Vasc Access* 2018; 19: 548–554.
26. Konner K, Nonnast-Daniel B and Ritz E. The arteriovenous fistula. *J Am Soc Nephrol* 2003; 14: 1669–1680.
27. Aruny JE, Lewis CA, Cardella JF, et al. Quality improvement guidelines for percutaneous management of the thrombosed or dysfunctional dialysis access. Society of Interventional Radiology Standards of Practice Committee. *J Vasc Interv Radiol* 2003; 14: 247–253.
28. Portugaller RH, Kalmar PI and Deutschmann H. The eternal tale of dialysis access vessels and restenosis: are drug-eluting balloons the solution? *J Vasc Access* 2014; 15: 439–447.
29. Doelman C, Duijm LE, Liem YS, et al. Stenosis detection in failing hemodialysis access fistulas and grafts: comparison of color Doppler ultrasonography, contrast-enhanced magnetic resonance angiography, and digital subtraction angiography. *J Vasc Surg* 2005; 42: 739–746.
30. Osterwalder J and Tercanli S. POCUS—chance or risk? *Ultraschall Med* 2018; 3: 606–609.
31. Narula J, Chandrashekhkar Y and Braunwald E. Time to add a fifth pillar to bedside physical examination: inspection, palpation, percussion, auscultation, and insonation. *JAMA* 2018; 3: 346–350.
32. Bhagra A, Tierney DM, Sekiguchi H, et al. Point-of-care ultrasonography for primary care physicians and general internists. *Mayo Clin Proc* 2016; 91: 1811–1827.
33. Hossain S, Sharma A, Dubois L, et al. Preoperative point-of-care ultrasound and its impact on arteriovenous fistula maturation outcomes. *J Vasc Surg* 2018; 68: 1157–1165.
34. Education and Practical Standards Committee, European Federation of Societies for Ultrasound in Medicine and Biology. Minimum training recommendations for the practice of medical ultrasound. *Ultraschall Med* 2006; 27: 79–105.