

Brief Report

Intestinal pseudo-obstruction following renal stone extracorporeal lithotripsy in a diabetic patient

Adamasco Cupisti¹, Roberto Spisni², Francesco Carlino², Ester Morelli¹, Fabio Zampieri², Mario Meola¹ and Giuliano Barsotti¹

¹Dipartimento di Medicina Interna and ²Dipartimento di Chirurgia, Università di Pisa, Pisa, Italia

Keywords: adynamic ileus; lithotripsy; pseudo-obstruction; renal stones

Introduction

Extracorporeal shock wave lithotripsy (ESWL) is the first choice treatment for renal calculi. Up to now, this approach was appropriate for almost all cases of urolithiasis whereas traditional surgery or percutaneous procedure were indicated only in a small number of complicated patients [1]. The efficacy and safety of ESWL have largely improved, although this procedure is not totally free from unwanted side effects or complications. Urinary tract obstruction, gross haematuria, subcapsular or perirenal haematoma, colic pain and infections are the most frequent complications and are seldom severe [2,3]. Extrarenal injuries including pancreatitis, splenic rupture, pulmonary contusions, colonic mucosal ecchymoses or cardiac arrhythmias have been sporadically reported [2].

We describe a case of adynamic intestinal obstruction which occurred in a diabetic patient following ESWL treatment of a renal pelvic calcium stone.

Case

A 61-year-old male patient was admitted because of chronic loin pain due to a kidney stone in the left renal pelvis. At 48 years of age type 2 diabetes mellitus was diagnosed and treated with oral anti-diabetic drugs for 3 years and then by insulin. Peripheral vascular disease was also reported. Two weeks before admission, the patient experienced left loin pain with gross haematuria. Sonography and plain radiography demonstrated a calcium stone in the left renal pelvis (Figure 1). Excretory urography confirmed the presence of a 18 mm diameter calcium-containing stone in the left

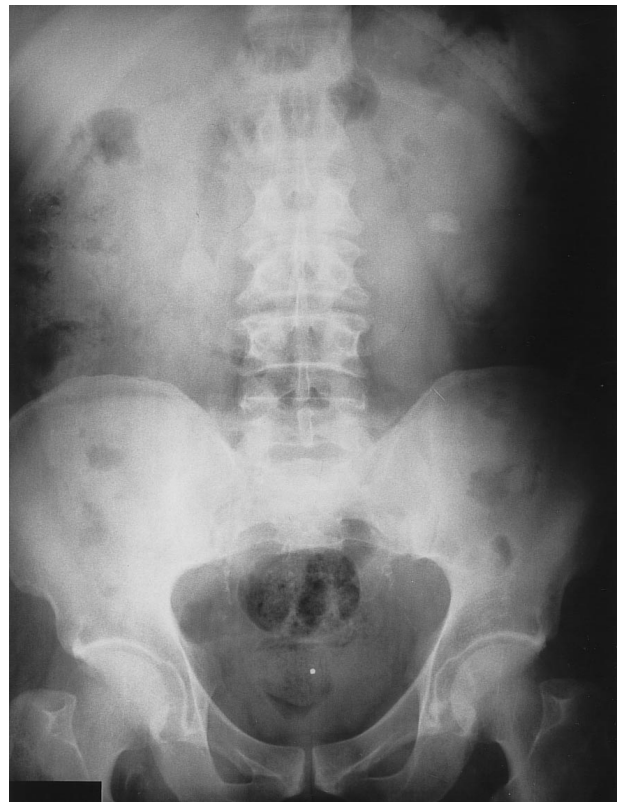

Fig. 1. Abdominal plain radiograph before ESWL, showing the calcium-containing stone in the left kidney. Bilateral vascular calcifications are also detectable.

kidney without significant dilation of pelvis or caliceal structures. Physical examination was unremarkable. The patient's body weight was 69 kg, body mass index 26.0 kg/m² and arterial blood pressure was 125/80 mmHg. Plasma biochemistry showed fasting glucose levels of about 150 mg/dl, HbA_{1c} 8.2%, and normal values for ALT, AST, pseudocholinesterase, creatinine, electrolytes and coagulation tests.

The patient was treated with ESWL in the morning. The duration of the session was 33 min and 1600 shock waves (14 000–17 000 V spark discharges) were

Correspondence and offprint requests to: Dott. Adamasco Cupisti, Dipartimento di Medicina Interna, Università di Pisa, via Roma 67, I-56100 Pisa, Italia.

delivered using a Dornier MFL 5000 Lithotripter [4]. Analgesia consisted of 30 mg ketorolac i.m. 30 min before the initiation of therapy. The ESWL session was well tolerated and the stone fragmentation was documented by X-ray monitoring. During the night, the patient complained of flank pain, nausea, and vomiting which was treated with 10 mg metoclopramide, 75 mg diclofenac and anti-cholinergic (40 mg *N*-butyl bromide joscine) administration. Later, some small stone fragments were passed. On day 2 after ESWL he had vomiting, painless abdominal distension with infrequent bowel sounds, but no clinical evidence of peritonitis. The next day, plain abdominal X-ray revealed distension of the large bowel, presence of gas in the rectum, some air-fluid levels in the small intestine (Figure 2) but no gas under the diaphragm. Sonography excluded the presence of renal, subcapsular or perirenal haematoma, retroperitoneal collection or fluid in the abdomen. The residual pelvic stone appeared fragmented and stone fragments were detected in the left ureter. Blood pressure values ranged from 120/65 to 145/80 mmHg. Biochemistry showed no significant changes in amylase (15 U/l), AST (11 U/l), ALT (14 U/l), LDH (323 U/l), and CK (42 U/l) plasma levels. The WBC count was 9800/mm³ and haematocrit was 38.7%. A rectal tube was inserted without relief. Colonoscopy was performed, but no organic obstacles and no mucosal bleeding were detected. He was treated with nasogastric aspiration

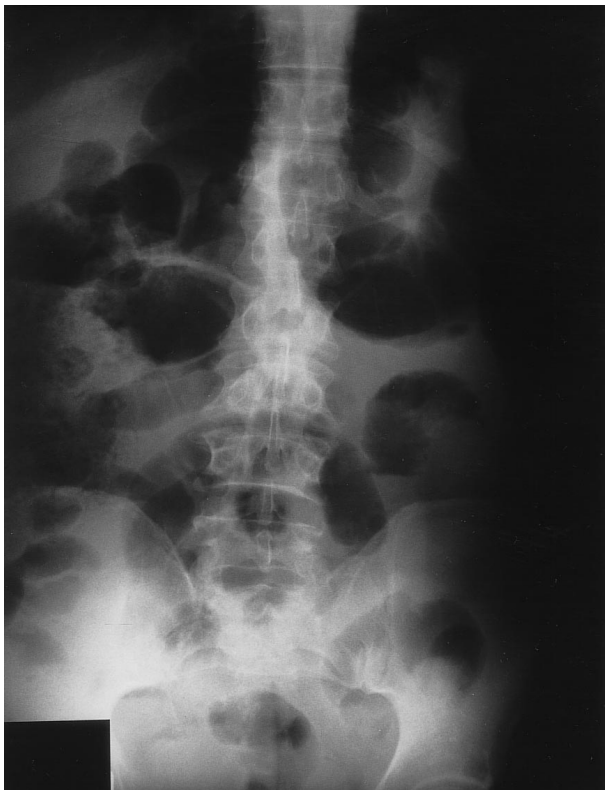


Fig. 2. Abdominal plain radiograph in stand-up position 3 days after ESWL. Large bowel distension, air-fluid levels in the small bowel and air in the rectum are present.

(using Cantor's device) and total parenteral nutrition for 5 days. Clinical and radiological conditions progressively ameliorated and 12 days after ESWL he was discharged. One week later, abdominal X-ray revealed no air-fluid levels, a reduced kidney stone (7 mm) and several small fragments in the lower third of the left ureter (Figure 3). The fragments were completely passed a few weeks later and the chemical analysis showed a calcium-oxalate stone composition. X-ray enema was also performed but no luminal or extra luminal lesions were observed. Subsequently, motor and sensory nerve conduction velocities were performed to assess peripheral neuropathy, but no alteration was found. Instead, autonomic dysfunction was demonstrated by the low heart rate variability and by the onset of postural hypotension during the tilting test (systolic blood pressure fell from 130 to 85 mmHg, at 60° position). Six months later, the patient underwent a second ESWL session to treat the residual stone in the left renal pelvis. The procedure was successful and totally free from complications.

Discussion

This case describes a complication following ESWL treatment of a urinary tract stone. ESWL was

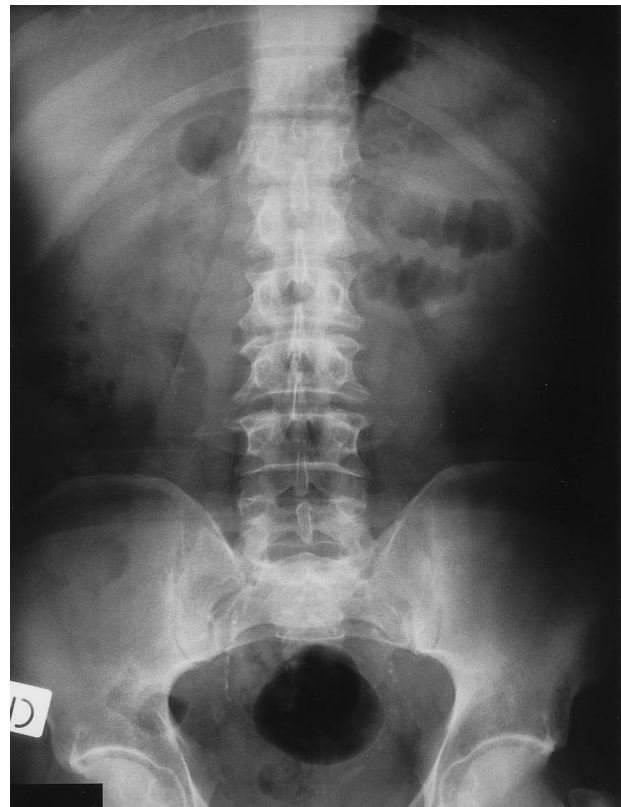

Fig. 3. Abdominal plain radiograph 3 weeks after ESWL treatment. The renal stone appears reduced in size, several small fragments are in the lower tract of the left ureter, no bowel distension or air-fluid levels are present.

successfully performed in terms of localization, fragmentation and clearance of stones, but an intestinal pseudo-obstruction syndrome occurred. The causes of this complication are speculative. Adynamic ileus could be induced by injury to the visceral or parietal peritoneal layer as in the cases of retroperitoneal bleeding, perirenal haematoma or pancreatitis, but none of these conditions was found in our patient. In addition, neither intestinal diseases nor relevant gastro-intestinal discomfort emerged from the history.

Acute pseudo-obstruction of the colon has been described in several situations including sepsis, cardiac failure, pancreatitis, pelvic or retroperitoneal surgery such as caesarean section or urologic interventions [5], but adynamic ileus following ESWL treatment has never been reported. The hypothesis of a retroperitoneal injury linked to ESWL, leading to bowel functional obstruction must be considered. The autonomic dysfunction, detected in this diabetic patient in the cardiovascular system and then probably also affecting the intestinal tract, could be an important precipitating factor. Moreover, the use of an anti-cholinergic drug could have contributed to reducing intestinal tract motility [5].

In summary, acute intestinal pseudo-obstruction occurred after ESWL treatment and anti-cholinergic drug administration in a diabetic patient. The cause of

this complication is uncertain. The temporal link to the ESWL session indicates that it may have been the inciting event, potentially favoured by diabetic autonomic dysfunction and by anti-cholinergic treatment. Then pseudo-obstruction of the intestine should be included in the list of the rare unwanted side-effects following ESWL treatment of urinary stones. It is noteworthy that early diagnosis and treatment of this condition is important to reduce the frequency of more serious complications.

References

1. Renner C, Rassweiler J. Treatment of renal stones by extracorporeal shock wave lithotripsy. *Nephron* 1999; 81 [Suppl. 1]: 71–81
2. Lingeman JE, Newmark JR. Adverse bioeffects of shock-wave lithotripsy. In: Coe FL, Favus MJ, Pak CYC *et al.* ed. *Kidney Stones, Medical and Surgical Management*. Lippincott-Raven Publishers, Philadelphia: 1996: 605–614
3. Copcoat MJ, Webb DR, Kellett MJ. The complications of extracorporeal shock wave lithotripsy: management and prevention. *Br J Urol* 1986; 58: 578–580
4. Graff J, Benkert S, Partor J, Senge T. Experience with a new multifunctional lithotripter, the Dornier MFL 5000: results of 415 treatments. *J Endourol* 1989; 3: 315–319
5. Clayman RV, Reddy P, Nivatvongs S. Acute pseudo-obstruction of the colon: a serious consequence of urologic surgery. *J Urol* 1981; 121: 415–417

Received for publication: 20.7.99

Accepted in revised form: 29.10.99